



Syncope is rarely a cerebrovascular symptom and neurovascular imaging is not indicated<sup>1</sup>

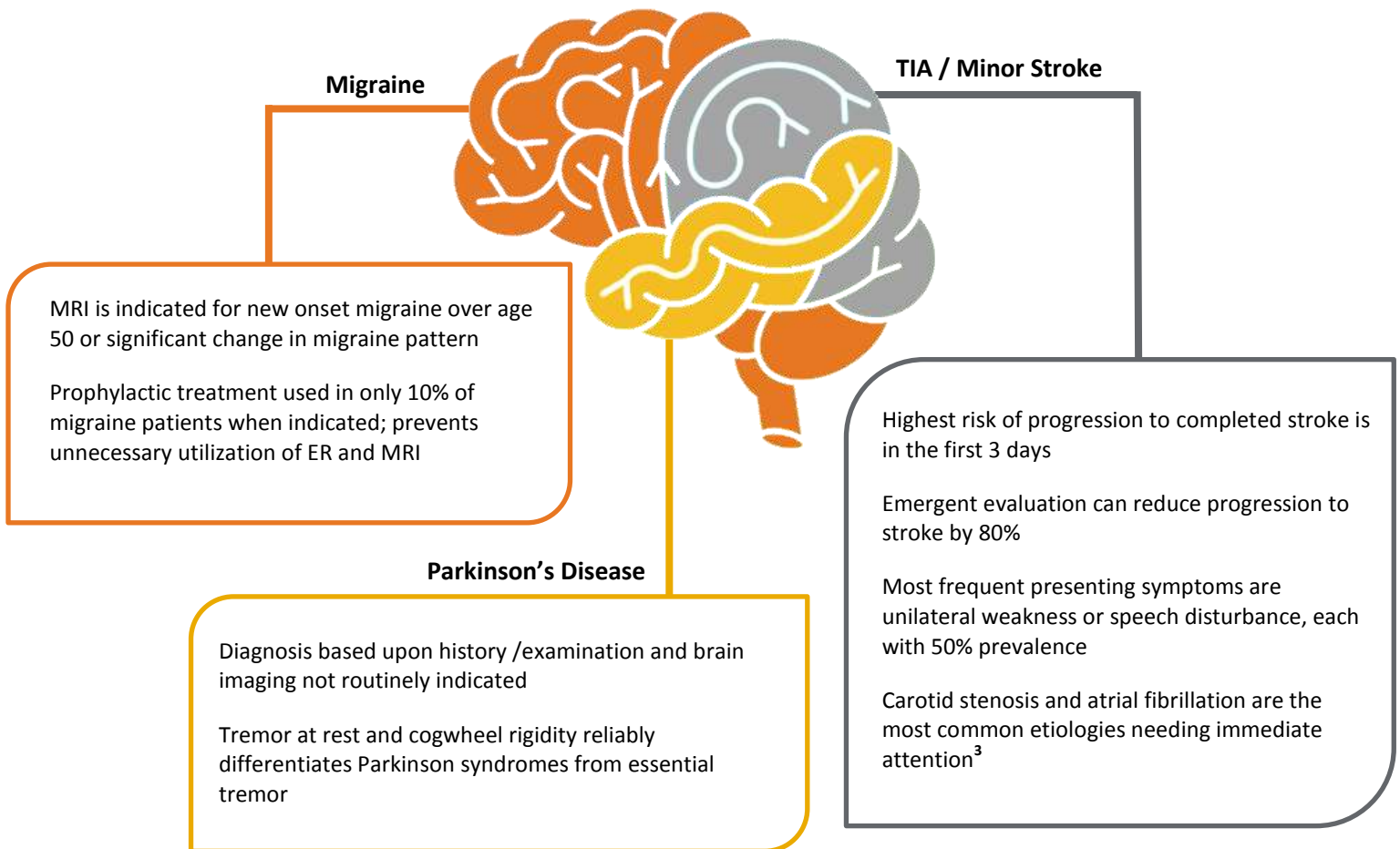


Isolated vertigo is a symptom of vertebrobasilar ischemia in < 1% of cases

## Asymptomatic Carotid Artery Stenosis<sup>2</sup>

- Ultrasound screening is not indicated
- Medical therapy is superior to surgical therapy
- 30 day stroke rate or death rate with carotid endarterectomy is 7%

## Management of Neurology Conditions



## Migraine Diagnosis

Migraine is underdiagnosed, criteria include:

- ✓ Five headaches lasting 4-72 hours in lifetime
- ✓ Severe enough to affect daily activities
- ✓ Associated with nausea or light/sound sensitivity
- ✓ Often misdiagnosed as sinus or muscle contraction headache

<sup>1</sup> Hanna, E. B. (2014). Syncope: Etiology and diagnostic approach. *Cleveland Clinic Journal of Medicine*, 81(12), 755-766. doi:10.3949/ccjm.81a.13152

<sup>2</sup> Lichtman JH, Jones MR, Leifheit EC. Carotid Endarterectomy and Carotid Artery Stenting in the US Medicare Population. *JAMA*. Sept 2017;1035-1046. doi:10.001/JAMA2017.12882

<sup>3</sup> Sacco, R. L., & Rundek, T. (2016). The value of urgent specialized care for TIA and minor stroke. *NEJM*, 374, 1577-1579. doi:10.1056/NEJMe1515730